

Restoration of the Endodontically Treated Tooth

Adapted from an article by Drs. Richard S. Schwartz and Richard Jordan

Before Root Canal Therapy

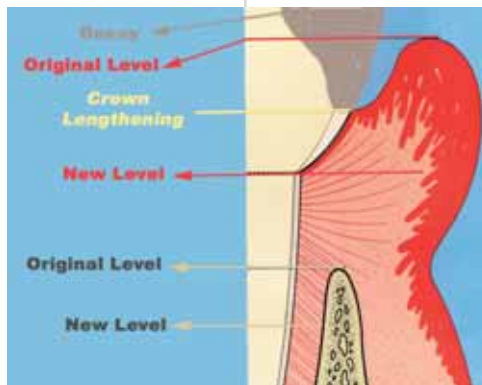
The best plan for success is to begin with the end in mind. Before initiating treatment, the practitioner should carefully examine the tooth for caries and fracture. The tooth should be assessed for restorability, occlusal function and periodontal health, and issues such as biologic width and crown-to-root ratio should be evaluated. If these factors are deemed satisfactory, the tooth can be included in the comprehensive treatment plan.

Whenever possible, practitioners should remove all existing restorations and caries before initiating root canal treatment. This allows more accurate assessment of restorability and evaluation for fractures. Teeth with extensive destruction of tooth structure may need crown lengthening or orthodontic eruption prior to endodontic treatment.

The Root Canal Treatment is Complete – Next step.....

Preventing contamination of the root canal system between completion of endodontic treatment and restoration of the tooth should be a primary concern. Contamination is thought to be an important cause of future problems in endodontically treated teeth. Therefore, an immediate restoration should be placed, whenever possible. Delaying restorative treatment is generally not in the best interest of the patient. Temporary restorations do not effectively prevent contamination for extended time periods.

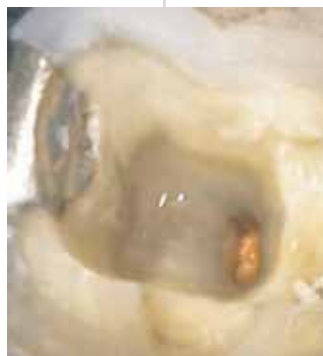When immediate restoration is not possible, orifice barriers should be placed to help protect the root canal system from salivary contamination. Bonded materials such as composite resin or glass ionomer cements are excellent choices. A traditional temporary material such as IRM or Cavit can be used in the access opening. However, the practitioner should be aware that the temporary restoration does not protect the tooth against fracture.



Sometimes endodontic treatment is performed through an existing crown. If the crown appears to be clinically acceptable, the access opening should be examined for dental caries. Dental caries detector substances can assist in the evaluation, as can magnification. Absence of

caries should be assured before the access opening is restored. If caries is present, the first choice is to remove the crown and remove the caries. If this is not practical, remove most of the caries and temporize the tooth as described above. The restorative dentist should then remove the crown and the remaining caries as soon as possible to minimize the chances of contamination of the root canal system.

Temporization of a post space presents a particular problem. Two recent studies showed that a temporary post and crown provided no more protection from contamination than controls without temporary restorations. If it is not possible to perform a post and core buildup immediately and a temporary post and crown are necessary for esthetic reasons, place a barrier over the gutta-percha at the base of the post space. The canal space should be maintained in a bacteria-free environment. Saliva should not come in contact with the canal and a rubber dam should be used during the restorative phase.



Restoration of the Endodontically Treated Tooth

Adapted from an article by Drs. Richard S. Schwartz and Richard Jordan

The Basic Principles of Restoration of the Endodontically Treated Teeth

The preponderance of the literature supports the following guidelines:

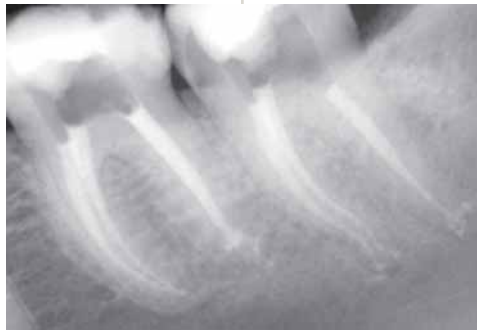- Posterior teeth with root canal treatment should receive cuspal coverage restorations. Bonded restorations, once thought to obviate the need for cuspal coverage, provide only short-term strengthening of the teeth, according to recent studies.
- Anterior teeth with minimal loss of tooth structure can be restored conservatively with bonded restorations
- Preservation of coronal and radicular tooth structure is desirable
- The purpose of a post is to retain a core buildup
- A ferrule is highly desirable when a post is used

An adequate ferrule is considered a minimum of 2 mm of vertical height and 1 mm of dentin thickness.

Posts

The purpose of a post is to retain a core that is needed because of extensive loss of coronal tooth structure. Practitioners should avoid using posts when other anatomic features are available to retain the core. Molars may not require posts because a core can usually be retained by the pulp chamber and canals. When a post is necessary, it should be placed in a distal canal in mandibular molars, and the palatal canal in maxillary molars, because the other canals tend to be thinner and more curved. Multiple posts are seldom indicated. Anterior teeth with extensive loss of coronal tooth structure usually need a post because the pulp chamber and single canal are generally not adequate to retain a

core. In addition, anterior teeth are subject to lateral forces during function, whereas posterior teeth are subject to primarily vertical forces. Premolars require clinical judgment because of their transitional morphology. The remaining dentinal structure will dictate whether a post is indicated to compensate for extensive loss of coronal tooth structure.



The use of a post carries with it a certain attendant risk of root fracture, particularly if sound dentin is removed during preparation. Preparation of a post space can also lead to perforation apically or a lateral strip perforation in the fluted portion of the mid-root. To avoid these problems, the practitioner who performed the endodontic treatment should prepare the

post space. Several studies have shown that the immediate creation of the post space may result in a better apical seal, although several studies also reported no difference.

Some of the area of general agreement regarding post design includes:

- When a post is needed, remove little if any additional dentin beyond what is needed to perform the root canal treatment
- Retain a minimum of 4 to 5 mm of gutta-percha apically
- Use a post designed to incorporate mechanical features that resist rotational forces
- Since forces concentrate at the crest of bone during function, place the post to extend apical to the crest of the bone. One “rule of thumb” is that the post should extend “into bone” at least as far as it protrudes “out of bone”

Should endodontic retreatment be necessary, “retrievability” is an important property of a post and should be considered in post selection.



Restoration of the Endodontically Treated Tooth

Adapted from an article by Drs. Richard S. Schwartz and Richard Jordan

Post Materials

Cast Metal Posts

For many years, cast metal posts were considered the standard. Although they are still used in some circles, they require more chair time than other posts and involve laboratory procedures and fees. In comparison studies, they generally do not perform as well as other types of posts. For these reasons, they are no longer widely used. Another disadvantage of cast metal posts is that they require temporization. The added procedures, time and need for temporization increase the possibility of contamination of the root canal system. On the positive side, there are several long-term clinical studies that report high success rates with cast gold posts. As well, they are easily removed for retreatment.

Prefabricated Metal Posts

These posts have been widely used for the past 20 years. They can be placed easily and quickly, and a core can be added and prepared at the same appointment. They are available in various metal alloys, some of which are quite strong and allow for the placement of a relatively thin post. They can usually be removed if retreatment of the root canal is necessary.

Most of the metal alloys contained in prefabricated contained in prefabricated metal posts are considered acceptable, with the exception of titanium alloys. Titanium alloys are generally weak and therefore not suitable for thin posts. In addition, post removal devices are often ineffective because of the softness of the metal. Titanium alloys have the same radiodensity as gutta-percha and are sometimes hard to detect radiographically.

Prefabricated posts are available in active or passive forms. Passive posts are recommended in most cases, but there are few indications for active posts, primarily in short

teeth where the retention is minimal. Because active posts have greater potential to cause root fractures and are more difficult to remove, passive posts are therefore preferred for most clinical situations.

Ceramic, Glass and Zirconium Posts

These materials have gained popularity because they are tooth-coloured and avoid esthetic problems in anterior teeth. The only way to remove nonmetallic posts is to grind them out with a bur, a tedious and dangerous procedure. Attachment of the core to the post can also be a problem with zirconium posts. These posts should be avoided because if retreatment is needed, it may not be possible, leaving surgery as the only option.

Fiber Posts

Most fiber posts contain either carbon fiber or quartz fiber. They have a modulus of elasticity similar to dentin, which allows them to flex with the root when under stress. This is believed to distribute the stresses more evenly throughout the tooth than metal posts, making the root less susceptible to fracture. Some studies have shown that fiber posts strengthen the root when used with resin luting cement, and several short-term clinical studies have reported high success rates.

The primary concern about fiber posts is whether they allow movement of the core during function or parafunction. If a post has the same modulus of elasticity as the root, but is much thinner in diameter, it will flex more under a load. This may cause leakage under the crown and buildup. Studies are currently underway to address this question and may lead to some reengineering of the current fiber posts. Any initial strengthening of the root by fiber posts is probably lost with time and function.

Carbon fiber posts are generally removed fairly easily by boring through the middle of the posts with an ultrasonic or rotary instrument. The alignment of the fibers assists in keeping the instrument moving in the right direction and thus helps prevent perforations. Quartz fiber posts are newer to the market, and there is some disagreement on their ease of removal.



Restoration of the Endodontically Treated Tooth

Adapted from an article by Drs. Richard S. Schwartz and Richard Jordan

Several short term clinical studies report high success rates with fiber posts. As recalls continue, researchers will be able to further assess their clinical efficacy.

Luting Materials

It is generally accepted that bonded posts are more retentive than cemented posts and provide a better seal. Most clinicians report that a bonded metal post is more difficult to remove than a cemented post. Surprisingly, this is not clearly shown in the literature. A bonded metal post is a double-edged sword. It is possible to get a better seal and perhaps better retention with a bonded post, but retrieval is more difficult. Fiber posts are designed to be used with resin cements, and their ease of removal is not affected by the cement. Generally speaking, if a post has adequate length and resistance form, satisfactory retention and seal can probably be attained with any of the luting agents and posts systems.

Conclusions

- ***Preserve coronal and radicular dentin***
- ***Avoid contamination of the root canal system***
- ***Restore the tooth immediately after root canal treatment if possible***
- ***Use posts only when necessary to retain a core buildup***
- ***Restore teeth in a way that allows for future retreatment of the root canal system***
- ***In most cases, the particular post system used is not as important as following the principles of adequate length, adequate resistance form, adequate strength to allow preservation of dentin, and an adequate ferrule. If these principles are followed, most post systems will perform well.***

Everything we do as dentists is temporary with the exception of extractions. We perform procedures with the idea that the results will be durable and long lasting, but none of them are "permanent". Our treatment planning process should reflect his reality.

